

Case Study—August 2011

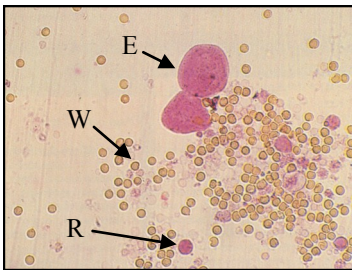
"Leo" is a 10 year old castrated male Himalayan who was in a 'spot of bother' when he started passing spots of blood instead of urine a few weeks ago.

Like many cats who suffer with this problem, Leo's urinary tract issues started years ago. At just 3 years of age, Leo had his first bout of cystitis (inflammation of the bladder). His parents noticed him straining in his litter tray and passing small amounts of urine often, and occasionally there were small specks of blood present too. A urine test was done to rule out infection, and then Leo was started on a Prescription diet to maintain the urine pH at the correct level and minimize the chances of repeated bouts of cystitis throughout his life.

Cats commonly develop a disease called **FLUTD** (Feline Lower Urinary Tract Disease). It is a complex disease with lots of causes including bladder infections, bladder stones, crystals in the urine and even bladder cancer. But the most common cause of FLUTD is 'idiopathic cystitis' or cystitis with NO known cause. It is a frustrating disease to treat because nobody knows why it occurs. Stress and infrequent urination seem to be the biggest risk factors.

Until recently, Leo's bladder issues were well managed on his special food. That was until he started to pass urine that looked like red wine!

Leo was assessed by a veterinarian, and apart from his painful bladder, he was otherwise very healthy. He was admitted to hospital to collect a urine sample for analysis in our laboratory, to monitor the amount of blood in his urine and to ensure the blood clots didn't block his urethra preventing him from urinating.



Slide showing epithelial cells of the bladder (E), red blood cells (R), and white blood cells (W).

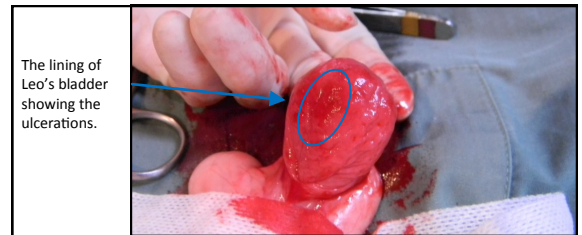
Leo's urine was bright red and contained lots of red and white blood cells indicating there was inflammation of the bladder lining. No bacteria were seen under the microscope, but urine was sent off to the external laboratory for bacterial culture to confirm this. Medications were started to settle the inflammation and provide pain relief. An antibiotic injection (which lasts for 2 weeks) was the perfect way to medicate Leo

because Leo 'the lap-cat' becomes Leo 'the lion' the minute he suspects tablets coming his way!



After 3 days in hospital, the urine culture results confirmed no infection, but the blood in his urine was not settling down at all. A blood test was done to make sure his kidneys were okay, and an ultrasound confirmed his bladder wall was very thickened. No bladder stones were visible and there were no polyps or masses present in the lining of the bladder. Leo was started on intravenous fluids to try to help flush the blood clots from his bladder and his anti-inflammatory medications were continued.

After a further 2 days there was still no improvement. Surgery to open the bladder to rule out cancer was the last option. The lining of the bladder had lots of tiny ulcerations and biopsies were taken and sent to the external laboratory to reach a diagnosis. The next 48hrs waiting for the results were the longest for Leo's worried parents. Luckily Leo loves attention and being in intensive care means lots of pats and cuddles.



The lining of Leo's bladder showing the ulcerations.

Thankfully after a week in hospital the anti-inflammatories and the drip finally started to work, and the blood in the urine gradually disappeared. By the time the results came back confirming Leo had severe 'idiopathic haemorrhagic cystitis' and NOT cancer, he was ready to go home.

There is always the possibility that Leo may have another bout of cystitis, but with his Prescription diet, his anti-inflammatory medications (which come as tasty chews!) and some stress relief....fingers crossed it won't be for another 7 years!

