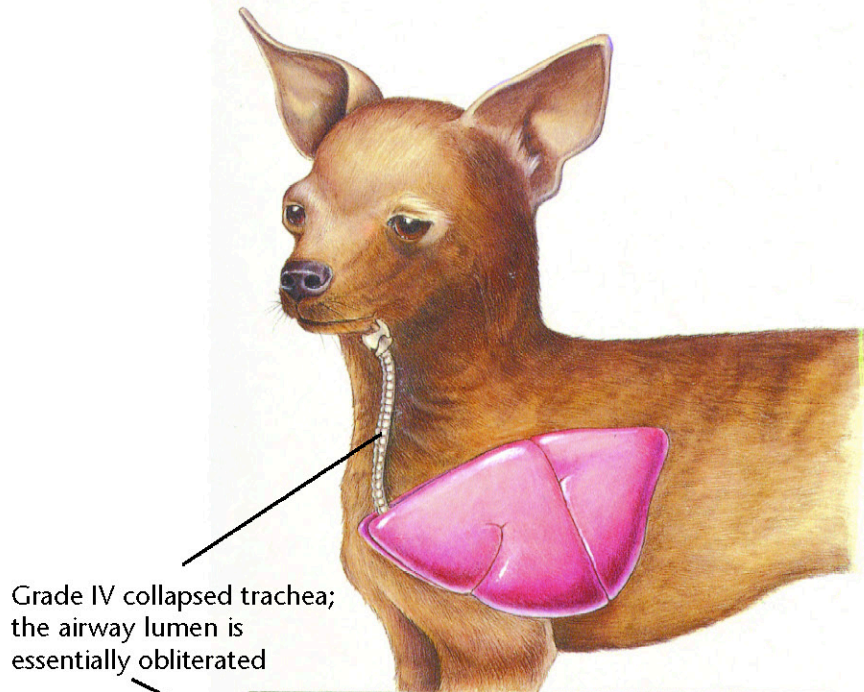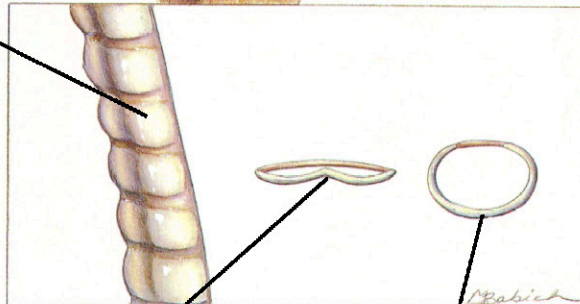


Grade IV collapsed trachea; the airway lumen is essentially obliterated



The tracheal cartilage is inverted dorsally and contacts the tracheal membrane

Normal tracheal ring

Collapsing Trachea

Diagnostic Plan

- History
- Physical examination
- Tracheal palpation
- Chest auscultation
- Chest x-rays
- Tracheoscopy
- Cultures of tracheal wash fluid

Therapeutic Plan

- Activity restriction
- Corticosteroids
- Steam vaporization
- Bronchodilators
- Antitussives
- Antibacterials
- Surgery

Dietary Plan

- If surgery is performed, a diet adequate for tissue repair
- If obesity is a complicating factor, restrict caloric intake so the patient reaches and maintains an ideal body weight

