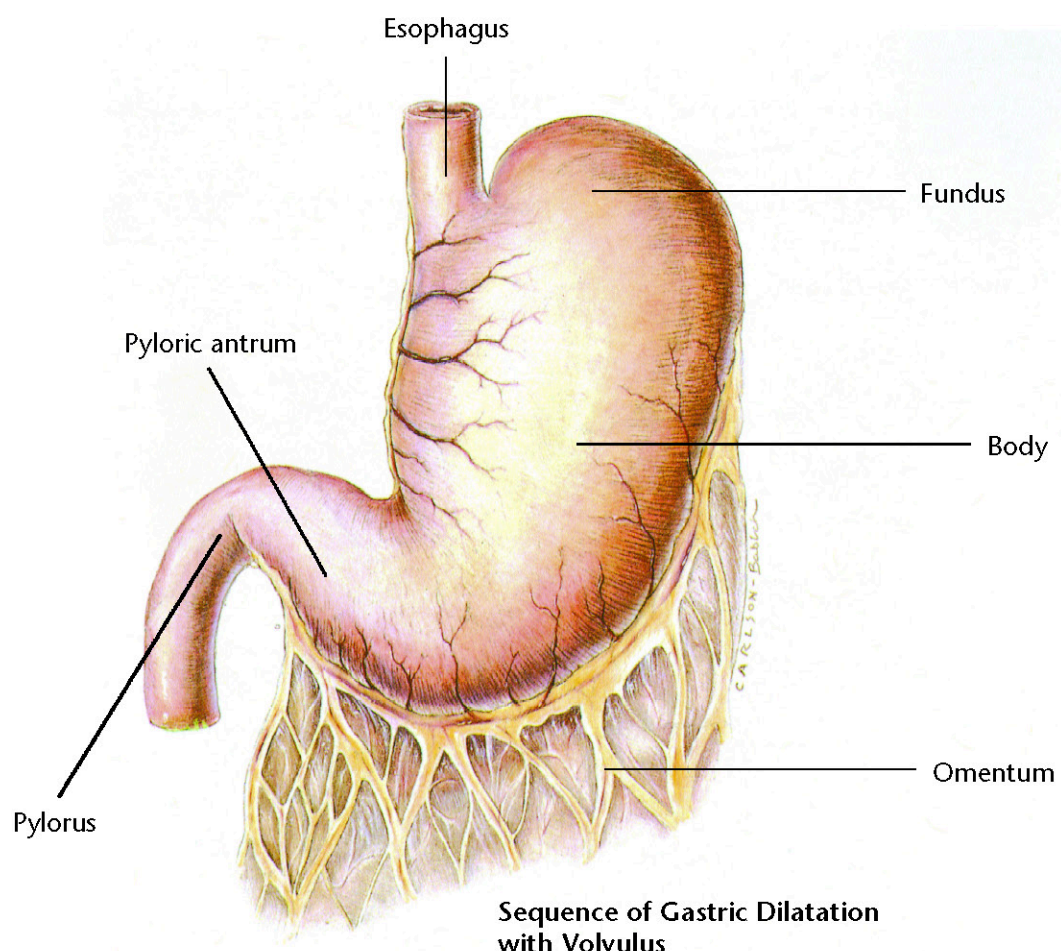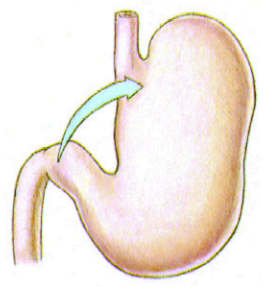
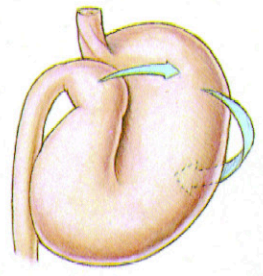


### Sequence of Gastric Dilatation with Volvulus

Clockwise rotation as viewed from a ventral position



The pyloric antrum is displaced downward.



The pylorus crosses the midline, passes underneath the distended proximal part of stomach, and moves upward along the left abdominal wall.

