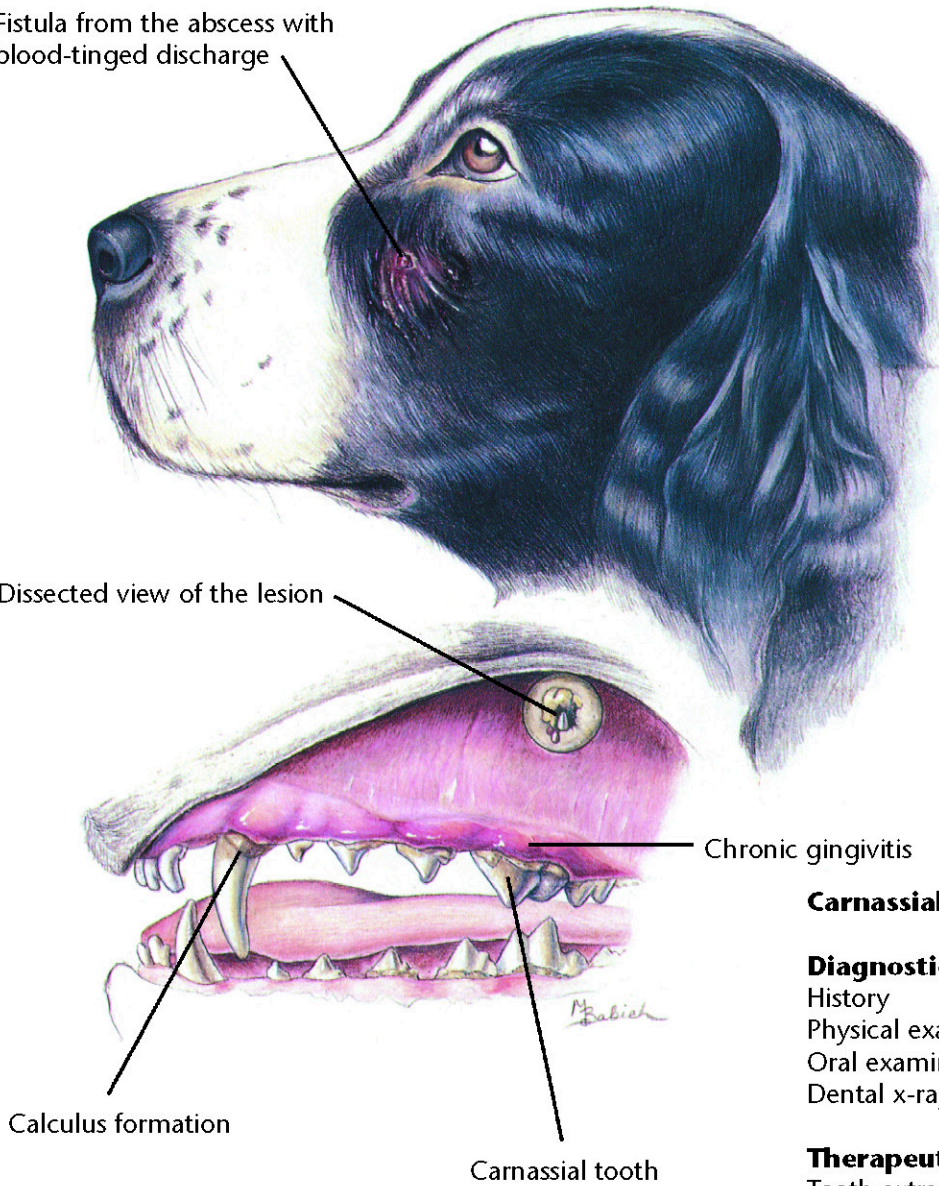


Fistula from the abscess with
blood-tinged discharge

Dissected view of the lesion



Carnassial Tooth Abscess

Diagnostic Plan

History
Physical examination
Oral examination
Dental x-rays

Therapeutic Plan

Tooth extraction
Root canals
Antibiotics

Dietary Plan

A diet based on overall patient
evaluation including body
condition and other organ
system involvement
A soft diet may minimize
postsurgical pain

